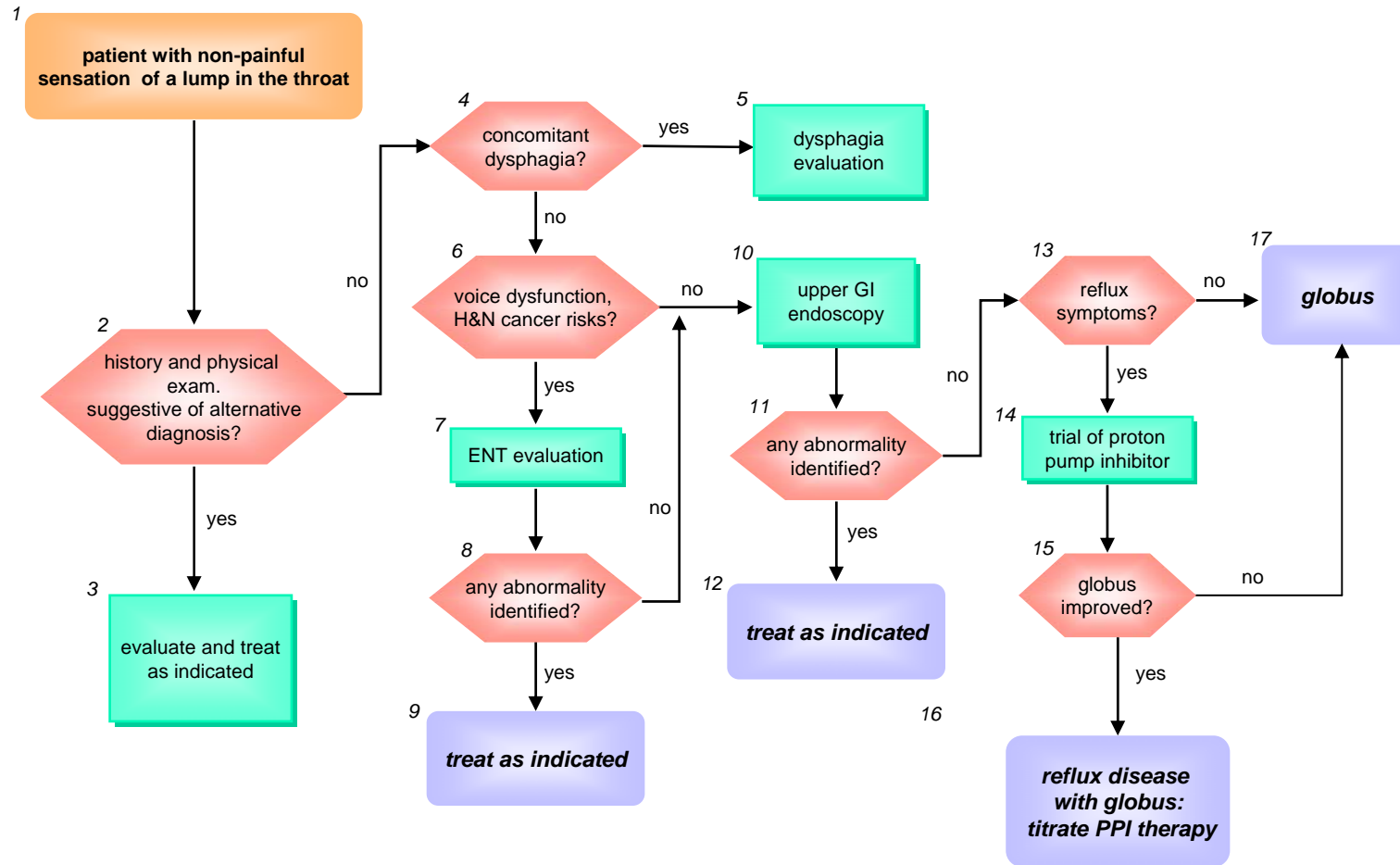


# Figure 4: Sensation of a lump in the throat



## Sensation of a lump in the throat

### *Case history*

A 30-year old small business owner consults her primary care physician (PCP) because of a feeling of a lump in the throat (Box 1, Fig 4). She has had this symptom intermittently for about one year, but the intensity has increased during the last few weeks. There was no obvious precipitating event. Her swallowing is normal, and not painful. There is no dysphagia (Box 4) or odynophagia, and no hoarseness or other change in her voice (Box 6). Eating improves the symptom. Yet, the patient has the impression that something is stuck in her throat. She rarely experiences heartburn, and has had no weight loss. The patient is otherwise healthy. She is a non-smoker and takes alcohol in moderation (Box 6). Apart from an oral contraceptive she does not use any drugs.

The PCP examines the patient's neck, throat, and oral cavity, but finds nothing abnormal (Box 2). There are no palpable masses, no enlarged lymph nodes and the thyroid is not enlarged. The PCP has the impression that the patient is experiencing some anxiety and explores whether the lump sensation is temporally related to stress, but the patient denies this association. The PCP, convinced that he is dealing with a functional disorder, explains to the patient that nothing is seriously wrong and attempts to reassure her.

However, two weeks later the patient consults her PCP again because of a continuing lump sensation. She is then referred to an ear-nose-throat physician because, in reviewing her history, she did have substantial exposure to second hand smoking and was quite concerned about this (Box 7). The latter does not find any abnormalities at examination which includes nasolaryngoscopy (Box 8). , Because of an association between globus and the endoscopic finding of ectopic gastric mucosa in the proximal esophagus and esophageal cancer, the patient is referred for endoscopy (Box 10). No abnormalities were found (Box 11). Because of the presence of some heartburn, 6-week trial of PPI therapy is initiated (Box 14). This does not lead to improvement of the lump sensation (Box 15). The patient is again reassured of the benign nature of her condition and a diagnosis of **globus** is made (Box 17).

## Figure legend

1. Globus sensation (Greek for “ball”) is the feeling of a lump or “ball” in the throat that is distinct from dysphagia in that it is experienced without swallowing and is even improved by swallowing; it is non-painful.
2. History and physical examination, especially of the neck, throat and oral cavity, may reveal evidence of trauma or an inflammatory or other condition potentially explaining symptoms.
3. Discovery of an alternative diagnosis sufficient to explain the symptom would preclude a diagnosis of globus.
4. Globus sensation can occur in association with dysphagia in which case diagnostic efforts shift to the evaluation of dysphagia.
5. Conditions associated with dysphagia would preclude a diagnosis of functional globus; see algorithm for dysphagia.
6. Globus sensation can occur in association with other symptoms of laryngeal dysfunction such as hoarseness which should prompt ear-nose-throat (ENT) evaluation. Similarly if a patient is at risk for laryngeal cancer because of smoking he or she should have an ENT evaluation (39)
7. ENT evaluation would likely include nasolaryngoscopy and other imaging as indicated (40-41).
8. Identification of an abnormality on ENT evaluation would preclude a diagnosis of functional globus.
9. Other ENT condition would prompt treatment as indicated.
10. Endoscopy is done to evaluate for ectopic gastric mucosa in the cervical esophagus or esophageal cancer which can be associated with globus sensation.
11. An abnormality identified at endoscopy would conclude the evaluation for functional globus. The finding of ectopic gastric mucosa in the proximal esophagus should prompt consideration of ablation therapy.

12. Other conditions should be treated as indicated.

13. Reflux disease can be a cause of globus and most GERD patients will not have macroscopic endoscopic findings. Hence patients with symptoms such as heartburn or regurgitation should undergo a therapeutic trial of antireflux therapy.

14. When used as a therapeutic trial in globus PPIs are usually given in a twice daily regimen(42).

15. Resolution of globus with PPI therapy would imply that the globus was a manifestation of reflux disease and exclude a diagnosis of functional globus.

16. Once a satisfactory treatment response has been established, the dose of PPI should then be reduced to the minimal dose still associated with a satisfactory treatment response.

**17. Rome III diagnostic criteria for globus are: 1) persistent or intermittent, nonpainful sensation of a lump or foreign body in the throat, and 2) occurrence of the sensation between meals, and 3) absence of dysphagia or odynophagia, and 4) absence of evidence that gastroesophageal reflux is the cause of the symptom, and 5) absence of histopathology-based esophageal motility disorders, and 6) criteria fulfilled for the last 3 months with symptom onset at least 6 months prior to diagnosis (26).**