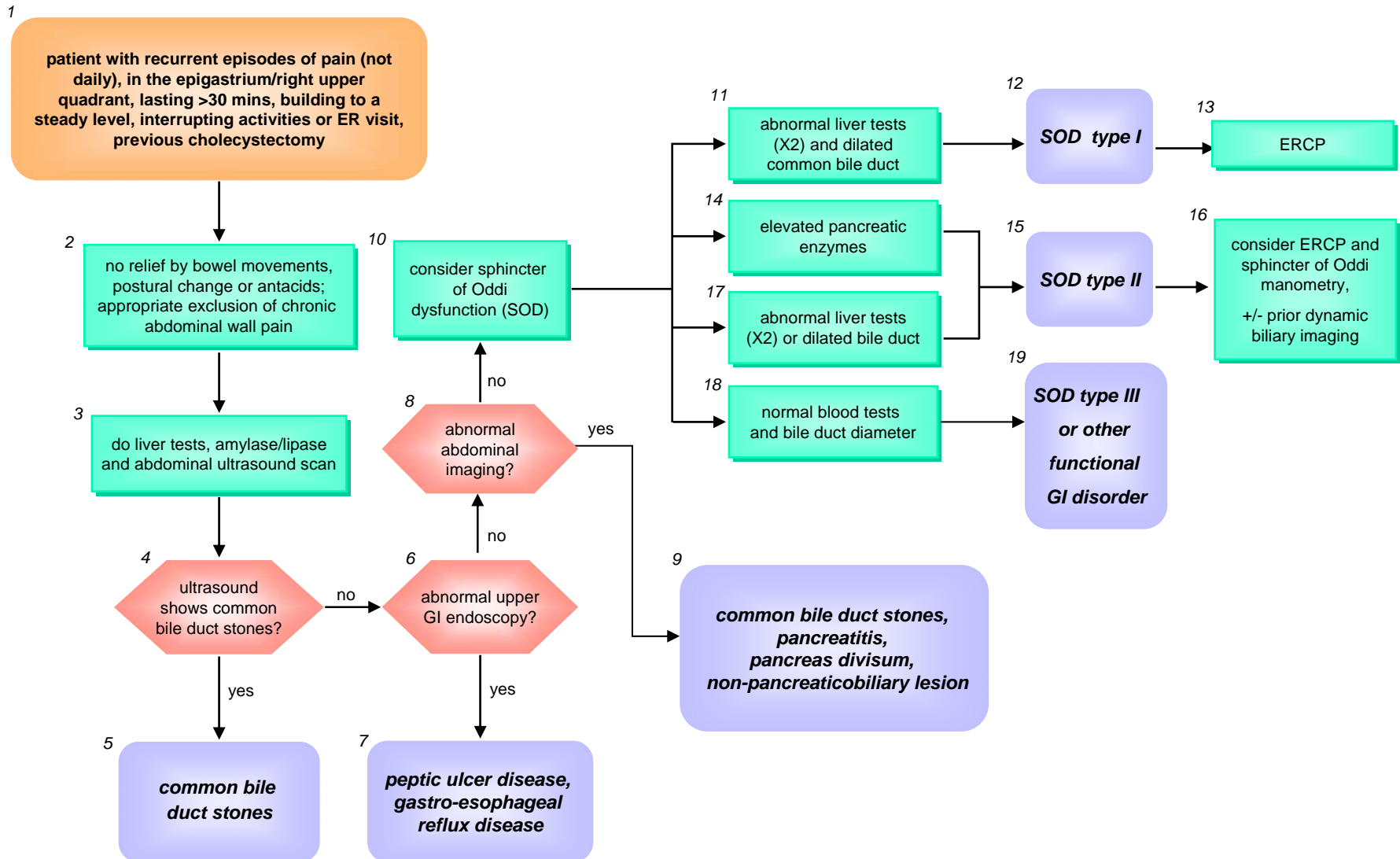


Figure 2: Post-cholecystectomy biliary-like pain



Post-cholecystectomy biliary-like pain

Case history

A 46 year old postal worker is referred to a gastroenterologist because of multiple episodes of severe right upper quadrant abdominal pain. On three occasions at several month intervals over the past two years the pain has required emergency room visits. Her previous medical history is negative except for a cholecystectomy performed for gallstones eight years earlier, following several episodes of uncomplicated biliary colic. Further analysis of the presenting pain by the gastroenterologist reveals that it increases to a maximum level and remains steady for more than 30 minutes (Box 1, Fig 2). At times the pain can radiate to the right subscapular region, and she has vomiting associated with the pain on some occasions. The pain has not woken her from sleep. There are no obvious precipitating factors, she has not used codeine-containing medications and the pain is not related to, or affected by, bowel movements; the pain is not relieved by antacids, posture or movement (Box 2). The pain is in fact, as far as she can remember, very similar to that which she experienced prior to her cholecystectomy. The patient does not admit to any gastrointestinal symptoms in the pain-free intervals. Physical examination is negative, including evaluation for an abdominal wall origin of pain (Box 2). The patient is not overweight.

Blood tests to assess serum liver biochemistry and pancreatic enzymes, and an abdominal ultrasound (US) scan, are performed (Box 3). The blood tests are normal. The US does not show bile duct stones (Box 4) but does show a common bile diameter of 12 mm (Box 8). At this stage, although the patient's pain appears most consistent with a biliary origin, the gastroenterologist wishes to exclude conditions such as gastro-esophageal reflux disease and peptic ulcer (Box 7), so performs an upper GI endoscopy (Box 6); this reveals no abnormality. The gastroenterologist considers further abdominal imaging and arranges an MRCP. This also shows no abnormality except for the dilated bile duct (Box 8). CT scan of the abdomen does not reveal any other intra-abdominal abnormality (Box 9). In the absence of structural disease, the gastroenterologist suspects that the typical biliary-like pain might be due to sphincter of Oddi dysfunction (SOD) (Box 10). Records

from the patient's previous emergency room visits reveal that her liver biochemistry and pancreatic enzymes were normal on each visit. Based on the lack of any abnormality on blood tests, but the presence of a dilated bile duct, a diagnosis of ***biliary sphincter of Oddi dysfunction type II*** is made. Knowing the risks of ERCP (with or without sphincter manometry) in such cases, the gastroenterologist refers the patient to a colleague with more experience. He considers quantitative choledochoscintigraphy, but for this case is not convinced by its discriminant value, and proceeds to ERCP (Box 16). Biliary manometry is abnormal and sphincterotomy is performed. Because the pancreatic duct was injected during the cannulation process, a small temporary pancreatic stent was placed to reduce the risk of pancreatitis.

Figure legend

1. This description of pain in patients previously submitted to cholecystectomy is considered to indicate a biliary-pancreatic origin, and suggestive of SOD (1). As with the previous algorithm, it is important to emphasize that the following diagnostic algorithm and discussion refers only to pain fulfilling all the specific features outlined.
2. These characteristics of the pain are suggestive of other conditions such as functional bowel disorder, acid-related disorder or musculoskeletal disorder (2), and should stimulate appropriate further investigation. Recurrent abdominal wall pain should be considered. Sphincter of Oddi pain and other functional gastrointestinal disorders can co-exist, so it may be appropriate to continue the diagnostic process according to this algorithm.
3. Laboratory blood tests of liver biochemistry and pancreatic enzymes, as well as noninvasive US, are performed to assess presence of biliary/pancreatic or liver pathology. Transient elevation of liver biochemistry and/or serum amylase/lipase within 24 hours of a pain episode may suggest sphincter of Oddi dysfunction (or stone passage).
- 4-5. Trans-abdominal ultrasound may detect biliary tract pathology, such as duct dilation and/or stones, and can detect some pancreatic lesions, leading to appropriate treatment. The sensitivity of ultrasound in detecting common bile duct stones is low. The acceptable size of the bile duct after cholecystectomy is controversial. Cholecystectomy itself does not increase the size, but the duct may be enlarged because of prior pathology, and it does increase slowly with age. The diameter of the common bile duct on ultrasound scanning on average is less than 6mm and does not exceed 10mm, even after cholecystectomy. Thus a common bile duct diameter greater than 10 mm is considered dilated (10).

- 6-7 Upper gastrointestinal endoscopy is unlikely to yield relevant pathology with this constellation of symptoms and when they are not alleviated by acid-suppression. However, it is wise to exclude reflux esophagitis and ulcer disease, and gastric cancer, especially in older patients.
- 8-9. Normal US findings, or the finding of a dilated bile duct only, with or without elevated liver biochemistry or abnormal pancreatic enzymes assessed after the episodes of pain, are indications to further investigate for potential structural causes with magnetic resonance cholangiopancreatography (MRCP), abdominal CT scan and/or endoscopic ultrasound (EUS) depending on the available resources and clinical suspicion. MRCP has 80-90% sensitivity for the detection of common bile duct stones. EUS has a diagnostic accuracy comparable to ERCP for the detection of common bile duct stones, with specificity of about 85-90% and sensitivity greater than 95% (11). EUS is the most sensitive imaging test for chronic pancreatitis, which is an important consideration in the differential of unexplained pain in this context. In older patients, it may be used to detect or exclude small tumors and IPMN.
10. Absence of structural abnormalities on these tests leads to consideration of biliary sphincter of Oddi dysfunction (SOD) as a cause of the pain.

Rome III diagnostic criteria (1) for functional biliary sphincter of Oddi disorder are 1) episodes of epigastric and/or right upper quadrant pain, lasting 30 minutes or longer and occurring at different intervals (not daily), with the pain building up to a steady level, being moderate to severe enough to interrupt the patient's daily activities or lead to an ER visit, and not being relieved by bowel movements, postural change or antacids 2) exclusion of other structural disease that would explain the symptoms present, and 3) normal amylase/lipase.

Supportive criteria are 1) one or more of associated nausea and vomiting, pain radiation to the back and/or subscapular region, and pain awakening the patient from sleep 2) elevated serum

transaminases, alkaline phosphatase, or conjugated bilirubin temporally related to at least two pain episodes.

- 11,12,13. The concomitance of transiently abnormal liver biochemistry shortly after at least two episodes of pain, with the finding of a dilated common bile duct, is diagnostic of biliary SOD type I, with an indication to consider ERCP and endoscopic sphincterotomy (12).
- 14,15, 16. The presence of elevated pancreatic enzymes is suggestive of SOD, with delay in the flow of pancreatic secretion, and constitutes an indication to consider ERCP and, in absence of structural alterations, to consider manometry of the biliary and, if clinically relevant, pancreatic sphincter of Oddi.
- 15,16,17,. Patients who have either a dilated bile duct, or abnormal liver biochemistry (but not both criteria), on two or more occasions, are classified as biliary SOD type II (12). These patients should be investigated further, but there is little consensus on the best approach (3). ERCP with biliary manometry was shown to be predictive of a good outcome after biliary sphincterotomy in one randomized trial 20 years ago (12), and this has become standard practice in referral centers. However, cohort studies show no better than 65% good outcomes with this approach, raising questions about the value of biliary manometry, and the need to study the pancreatic sphincter also. ERCP with manometry carries a significant risk of post-procedure pancreatitis (reduced recently by temporary pancreatic stent placement), so there have been many attempts to develop non-invasive diagnostic tests. Evidence for and against sphincter dysfunction can be obtained by studies of dynamic biliary imaging. Several now obsolete methods have been proposed, including measurement of the bile duct size before and after a fatty meal, or after injection of cholecystokinin (CCK) (1,13). Nuclear medicine

imaging, assessing choledochoscintigraphy with (11) or without (15) CCK provocation has been reported to offer more reliable information. The optimum method for choledochoscintigraphy, and the predictive value of the results, remain somewhat controversial (13-17). They may guide clinicians towards proceeding to sphincter manometry if positive, or away from the procedure and attending to other treatments if negative. In practice, such nuclear medicine imaging is not often undertaken, and patients with severe symptoms and these parameters are usually referred for ERCP with sphincter manometry. There are some proponents of intra-sphincteric injection of Botox as a valid therapeutic trial (18). Dynamic MR scanning may have a role in the future. The risk of causing pancreatitis by ERCP with or without sphincter manometry in patients with suspected SOD can be reduced by placing a temporary pancreatic stent (3). For all of these reasons, it seems prudent to refer these patients to tertiary centers for comprehensive assessment. Those centers are encouraged to undertake research studies to advance our knowledge.

19. With normal liver biochemistry and normal common bile duct size, a diagnosis of biliary SOD type III, or other functional GI disorder (such as functional abdominal pain syndrome or epigastric pain syndrome), is likely. A therapeutic trial with proton pump inhibitors, antispasmodic drugs, or an antidepressant agent should be considered. The role of ERCP and manometry in patients with SOD type III remains to be clarified.